TWIN

Introduction

- Two or more fertilization events
- Single fertilization followed by splitting of zygote
- Combination of both

TWIN PREGNANCY:

twin pregnancy means a women is carrying two fetus at a same time

TYPES:

there are two types of twins

1. Monozygotic (identical twins)
2. Dizygotic (fraternal twins)

MONOZYGOTIC

-IDENTICAL

-Same placenta

-FERTILIZES BY SINGLE OVUM

-SAME SEX

-SAME BLOOD GROUP

DIZYGOTIC

-NOT IDENTICAl

-Separate placenta

-FERTILIZED BY 2 OVUM

-DIFFERENT SEX

-DIFFERENT BLOOD GROUP

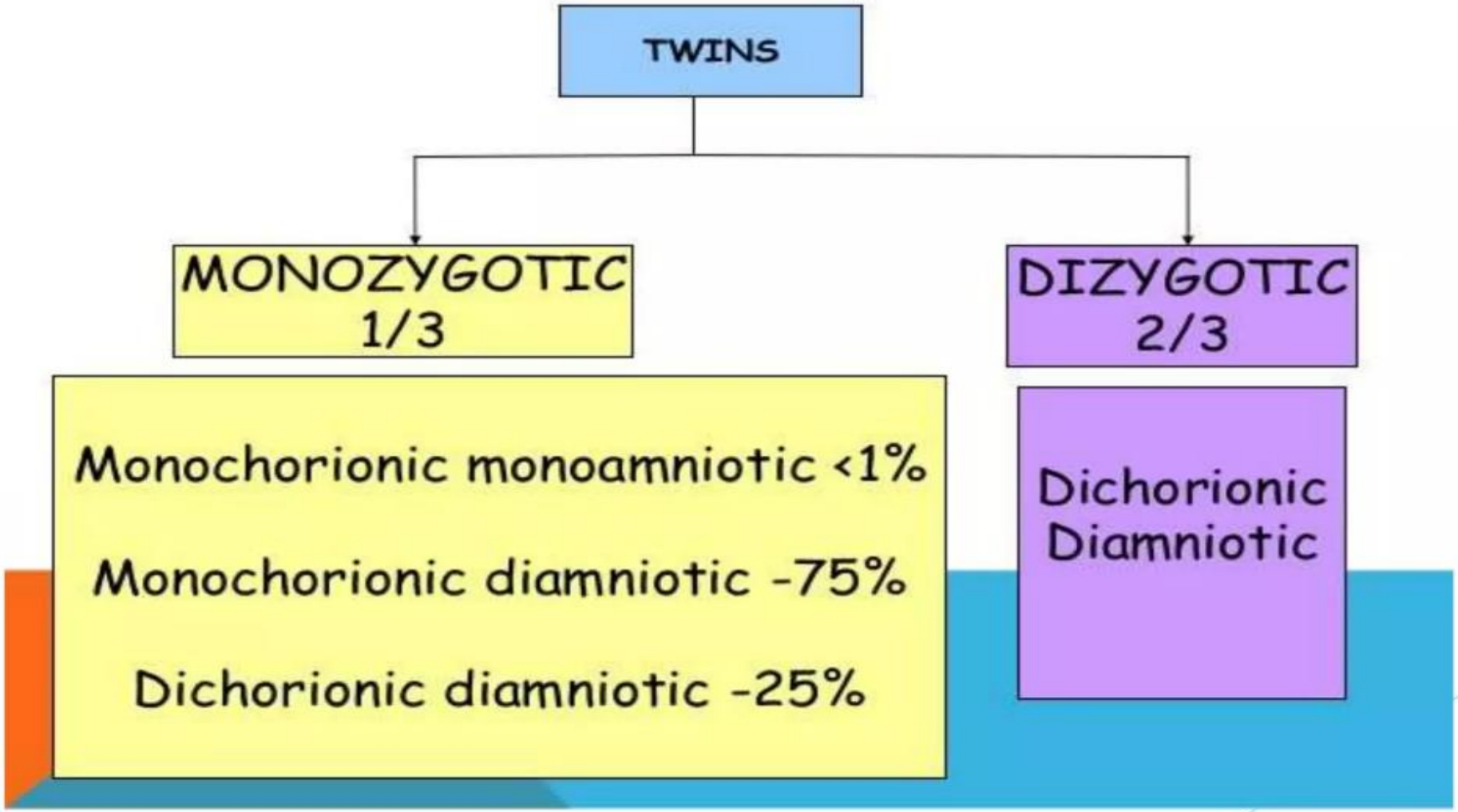
TWINS
MONOZYGOTIC
1/3
DIZYGOTIC
2/3
Monochorionic monoamniotic <1%
Monochorionic diamniotic -75%
Dichorionic diamniotic -25%
Dichorionic
Diamniotic

MONOZYGOTIC TWINS :

- Monozygotic means “one zygote.”

- MZ twins develop when one egg is fertilized by one sperm to produce a single zygote.

- The zygote starts to develop into an embryo

- but at some time during the first two
- weeks the developing embryo splits int
- two identical parts.

- Each part develops into a baby.

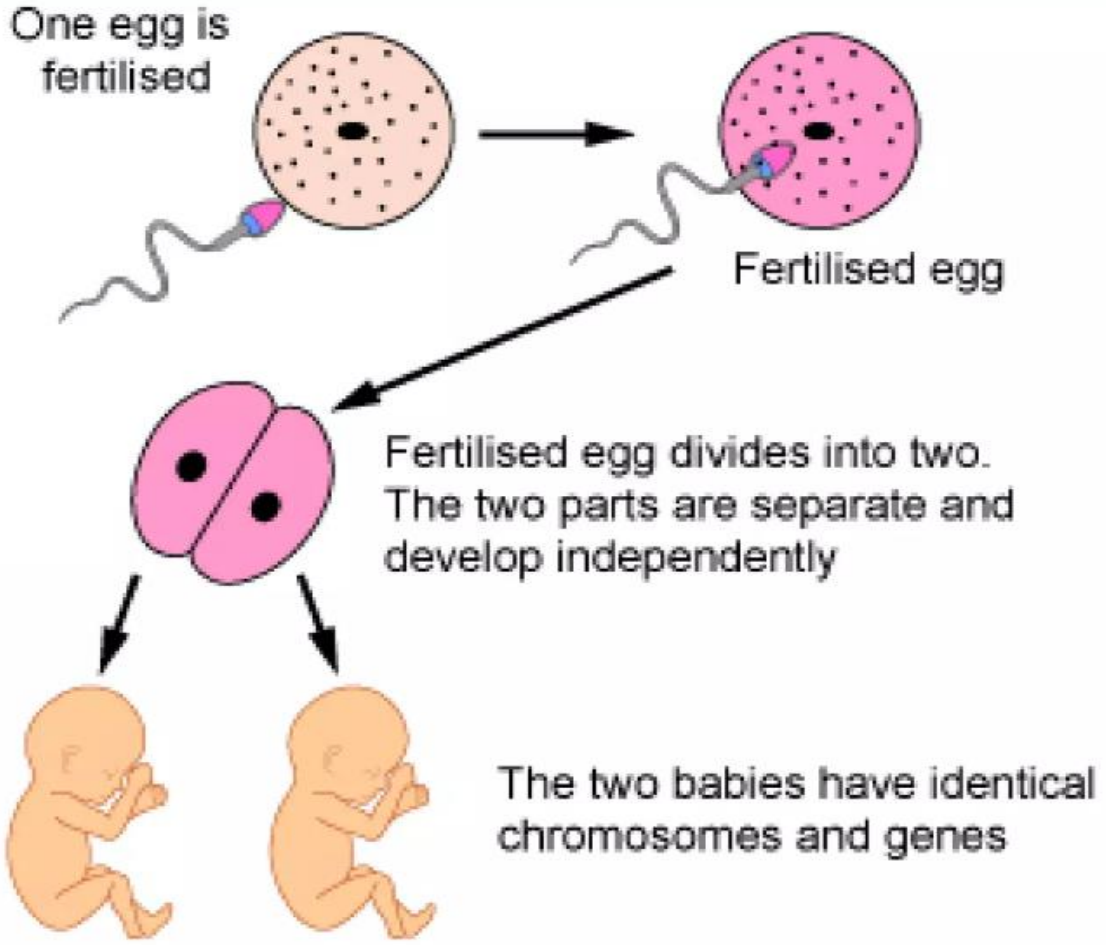

TYPES OF MONOZYGOTIC TWINS :

- Due to the arrangement of placenta and membranes it is divided into 4 types
- These type depends on division of zygote
- MONOZYGOTIC twins have same placenta

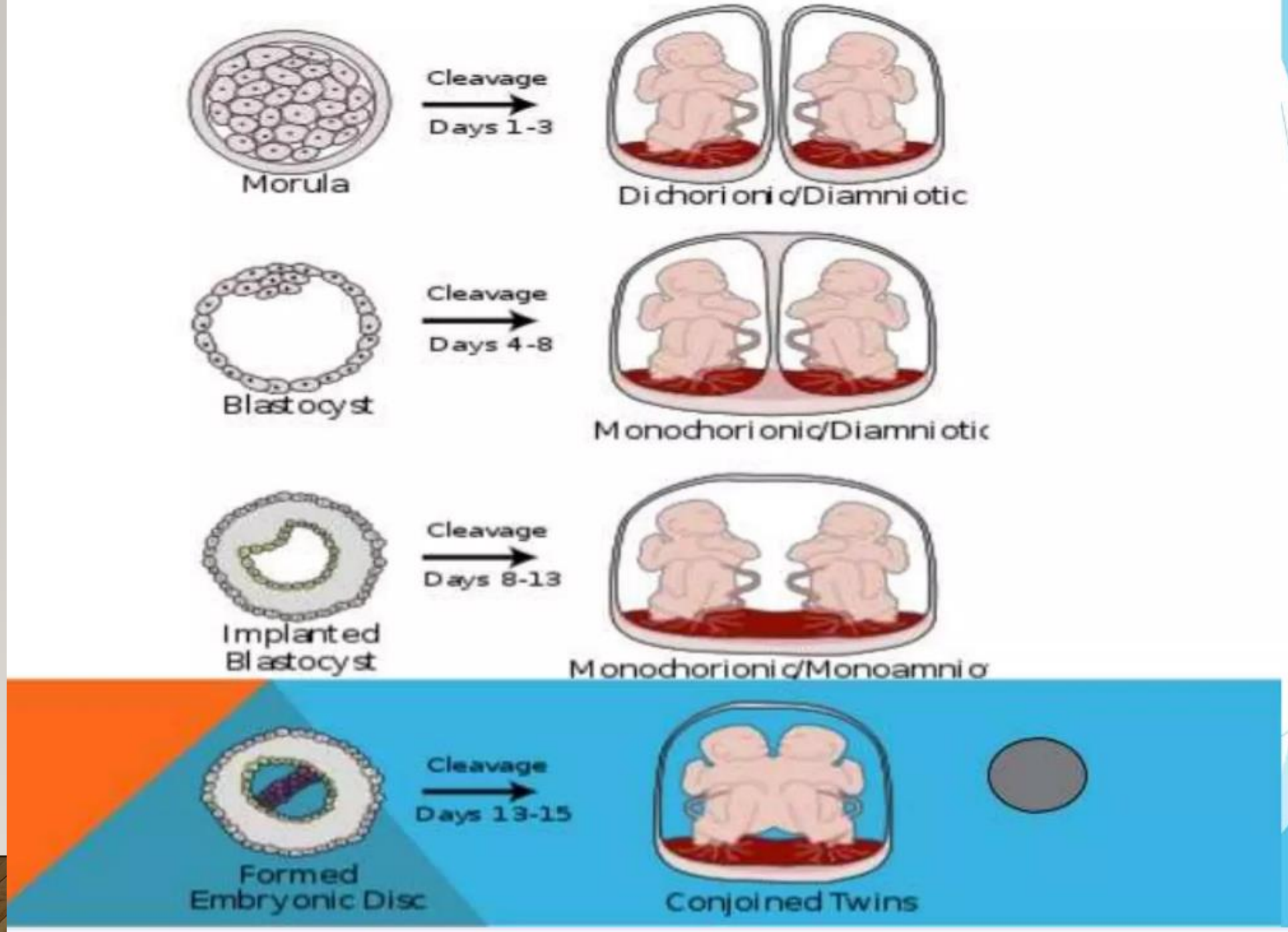
Morula
Cleavage
Days 1-3
Dichorionic/Diamniotic
Blastocyst
Cleavage
Days 4-8
Monochorionic/Diamniotic
Implanted Blastocyst
Cleavage
Days 8-13
Monochorionic/Monoamnio
Formed Embryonic Disc
Cleavage
Days 13-15
Conjoined Twins

DIZYGOTIC TWINS :

- These are always DICHORIONIC and DIAMNIOTIC
- Dizygotic means “two zygotes.”
- Two eggs are fertilized by two different sperms
- Forms 2 zygote
- These zygotes are implanted into
- uterus seperately

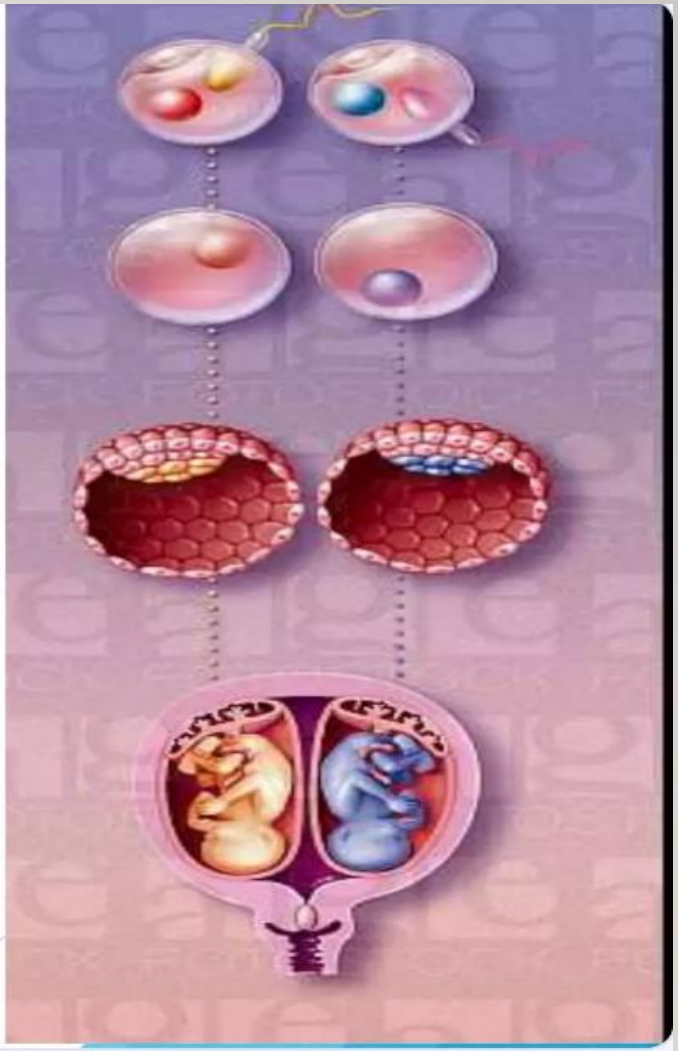

Dizygotic

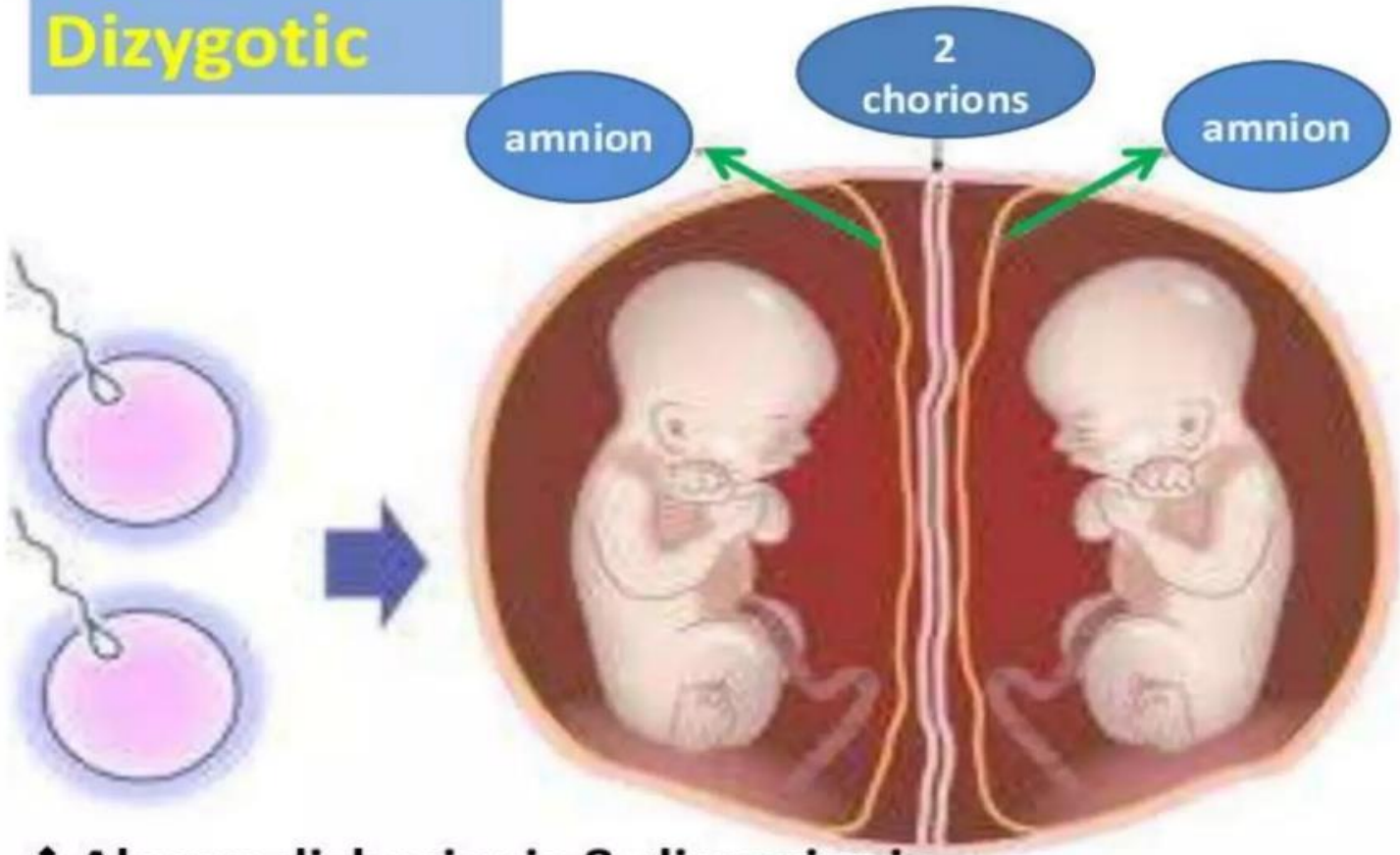

❖ Always dichorionic & diamnionic

Dizygotic
(Dichorionic, Diamniotic)

Determination of zygosity/ chorionicity

- Chorionicity can be identified in the first trimester with sonography
- Before 10 weeks sonographic findings to determine chorionicity.
- Number of

1. gestational sacs
2. amniotic sacs within the chorionic cavity
3. yolk sacs.

1. Number of Gestational Sacs

Each gestational sac forms its own placenta and chorion:

2 gestational sacs: DC twin

1 gestational sac with 2 identified heartbeats: MC twin

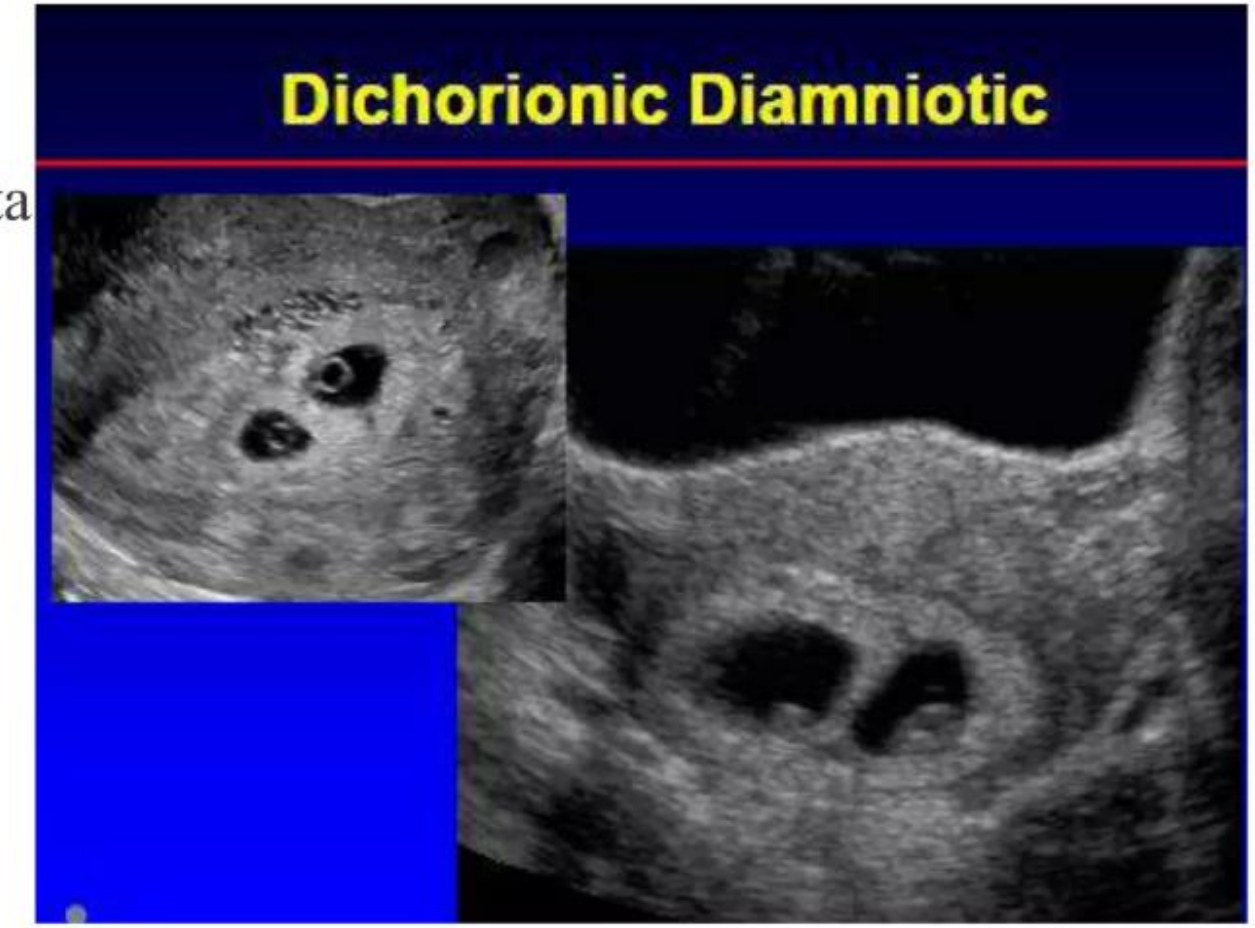

2. Number of Amniotic Sacs Within the Chorionic Cavity

- Diamniotic twins: separate and distinct amnions
- before 10w the separate amnions of a diamniotic pregnancy will not have enlarged sufficiently to contact each other and create the inter-twin septum.
- TAS: Each single amnion is extremely thin and delicate: very difficult to see TVS: often successful in differentiating separate amnions.

3. Number of Yolk Sacs

- 2 yolk sacs are seen in the extra-embryonal coelom: diamniotic
- 1 yolk sac

--in most cases indicate monoamniotic twins

-- when there are dual embryos: a follow-up 1st T scan to definitively assign amnionicity.

Dichorionic twins
Monochorionic twins

Aberrant twinning mechanisms

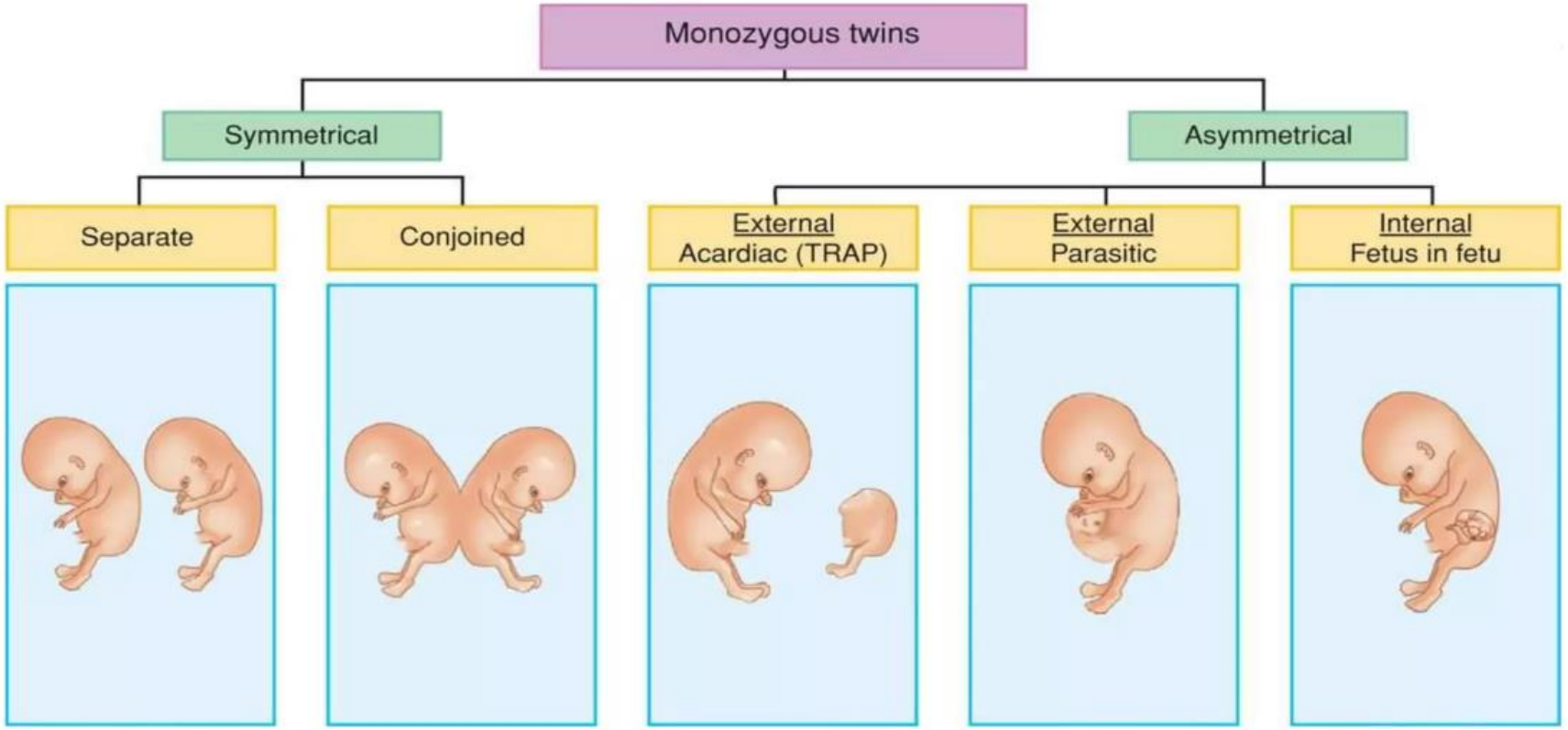

Conjoined twins

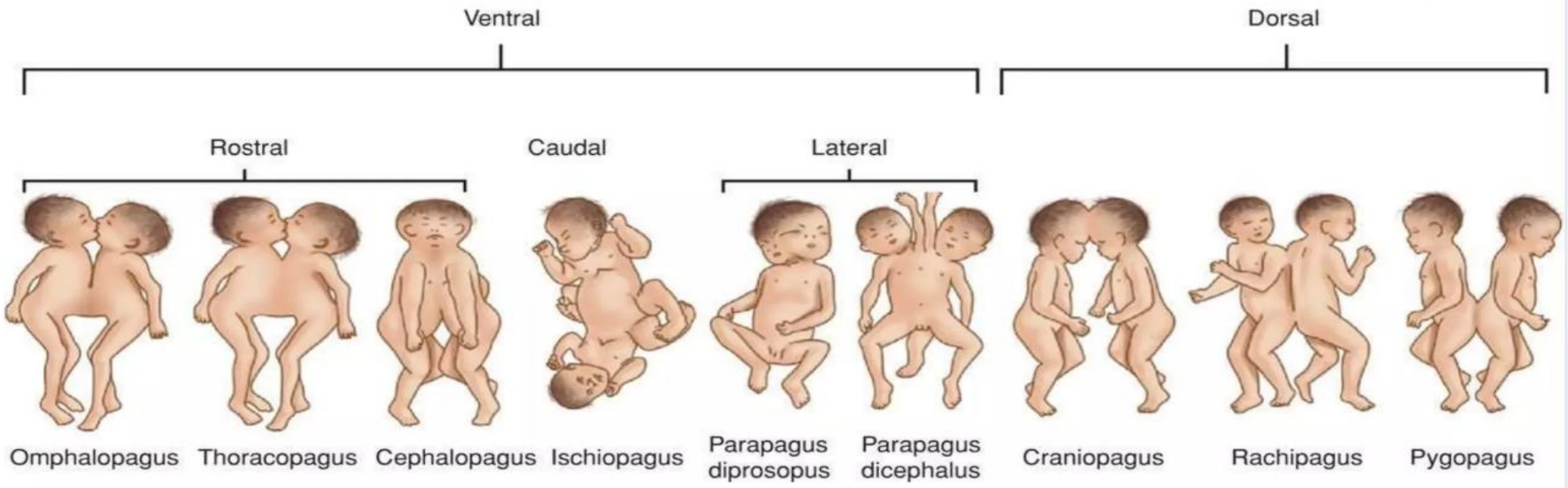

Keys to remember

- Multiple pregnancies are at increased risk of pregnancy complications that singletons
- Pregnancy outcome of multiple pregnancy is mainly determined by the chorionicity
- First trimester USG is very reliable in determining accurate pregnancy dating, chorionicity, orientation and abnormal twin gestation
- Monochorionic twins should be monitored more often between 16- 24 weeks for early diagnosis of fetal transfusion syndromes
- Fetal growth of the multiple pregnancy should be monitored 4 weekly from 26-38 weeks

Thank you


WELL, MEREDITH, I WOULD SAY ONE OF YOUR TWINS IS SOMEWHAT SHY AND THE OTHER ONE SEEMS TO WANT TO MAKE A DEFINITIVE STATEMENT ABOUT HIS GENDER.
PregnancyHumor.com